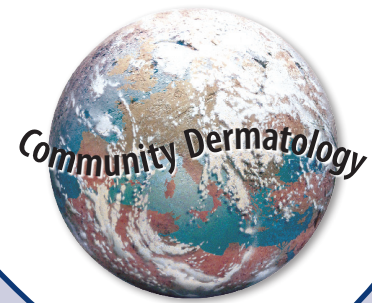

# Community Dermatology

*J Comm Dermatol* 2009; 6: 13-24

Issue No.10



## THE INTERNATIONAL FOUNDATION FOR DERMATOLOGY AND COMMUNITY DERMATOLOGY

Rod Hay DM FRCP FRCPath  
Chairman, *The International Foundation for Dermatology*

Paul Buxton MBBChir FRCPEd  
Editor, *Community Dermatology Journal*

### Background

The Editorial of the first Issue of the Journal in 2004 included these words:

'The objectives of the Journal are to bring up-to-date, relevant information on the diagnosis and treatment of skin disease to health workers in rural areas, using the resources available to them. It also sets out to provide information that can be used to educate health workers and the populations they serve.'

Since then, the Journal has been able to fulfil this aim due to the commitment of the Editorial Board and high standard of material submitted. The vision for the Journal came initially from Murray McGavin and the ICTHES Trust, which no longer exists. It is now produced by the International Foundation for Dermatology (IFD), which provides the resources of its base in London and the services of a part-time administrator.

### The International Foundation for Dermatology

The International Foundation for Dermatology (IFD) was established over 20 years ago and is part of the International League of



*Community Dermatology Pharmacy in Mexico*

Photo: Rod Hay

Dermatology Societies (ILDS). The ILDS provides a global forum for the world's Dermatology Societies by, for instance, organising the World Conferences of Dermatology or through its formal links with the World Health Organization.

The IFD was developed in response to the recognition that there was little care available for patients with skin problems in many parts of the world, often because there were no, or too few dermatologists or where the local health care depended on health care workers with little training in the management of skin disease. Although there has been a remarkable increase in medical facilities in developing countries, these are largely in urban areas and the majority of the population have only limited access to them. So the training and equipping of health workers in the community is vitally important.

In common with the *Community Dermatology Journal*, the chief objective of the International Foundation for Dermatology is to improve dermatological care in the developing world, and this remit covers not only skin disease but, also, sexually transmitted diseases and leprosy. It also extends beyond the diagnosis and treatment of skin conditions to include early recognition of condi-

### CONTENTS

*J Comm Dermatol* 2009; 6: 13 – 24 ISSUE No. 10

<b>EDITORIAL:</b> The IFD and <i>Community Dermatology</i>	Rod Hay, Paul Buxton	13
<b>JOURNAL EXTRACTS</b>	Neil H Cox	15
<b>TRIBUTE:</b> Neil H Cox	Paul Buxton, Christopher Lovell	16
<b>LEAD ARTICLES</b>		
Hazards of Skin Bleaching Agents	Mahreen Ameen, Beatrice Etemesi	16
Human Dermal Myiasis	Christopher Lovell	19
Scabies and Myiasis in Nigeria	Lucy Airauhi, A O Airauhi	21
<b>QUIZ:</b> Genital Lesions	Kassahun Desalegn Bilcha	21+23

# The IFD and Community Dermatology

tions that present with skin signs and symptoms, including those with serious implications for health, such as HIV or onchocerciasis. The work of the IFD is mainly:

- Education and training of health workers in the recognition of disease with skin changes and effective pathways of management of these conditions.
- Promotion of better services in areas where skin or sexually transmitted diseases are both common and poorly managed through lack of trained personnel or resources.
- To provide a link with the World Health Organization as part of the ILDS.

In considering how best to accomplish these aims, the Foundation has focused on two activities in particular, education and training and the assessment of dermatological need. The latter is important as it provides information on the range of skin diseases that are common at community level, as well as their impact, and helps to identify possible routes of improvement.

## Programme

Skin disease often appears a small player in this big league of international health programmes and little attention has been paid to the alleviation of this problem, although skin disease often dominates the pattern of illness at village or community level because it is so common.

Where endemic disease, such as onchocerciasis or lymphatic filariasis are common they may present with signs and symptoms in the skin. Poor treatment exacerbates the problem because it fails to alleviate the condition and has a wider impact on continuing ill health, as well as affecting local micro-economics through erosion of household budgets.

## Training

The first project of the IFD was the establishment of a training centre in Sub-Saharan Africa. The **Regional Dermatology Training Centre (RDTC)** in **Moshi, Tanzania**, was created in partnership with the Tanzanian Ministry of Health and the Good Samaritan Foundation. The principal objective of the Centre is the care of skin disease seen in locality, together with training leaders of health care at front line level, usually senior clinical officers or nurses, through a two year University based Diploma course. A second training scheme (MMed) provides for a four year specialist training in dermato-venereology for junior doctors, which is now a training pathway recognised for specialist accreditation by several African countries.

The Diploma course has trained over 240 senior clinical officers from over 15 different countries. The students have also performed health service research projects as part of their training and these provide a unique insight into prevalence, need and demand for health care at community level. With time, other facilities such as a library, a pharmaceutical compounding unit, a student hostel, and accommodation for visiting teaching faculty have been added. The first Director of the Centre was Professor Henning Grossman and he was succeeded by the current Director, Professor Jon Masenga. Together they have established a service and training programme covering all aspects of dermato-venereol-



*Professor Henning Grossman and Professor Jon Masenga at the Regional Dermatology Training Centre (RDTC) Board meeting in Tanzania*

*Photo: Rod Hay*

ogy, helped by visiting teaching faculty and a strong and expanding local team, which has allowed the development of specific initiatives, such as a regional albino programme. The latest project is an inpatient ward, which will be linked to other facilities, such as a plastic surgery and burns unit.

A different programme in **Mali**, based on the support of French speaking doctors and nurses at primary care level has targeted training for primary health care schemes, with the support of the national government. This initial phase of education covering training in different regions of the country will be completed within the next two years. This work, initiated by Dr Antoine Mahé, and now continued under the guidance of Dr Ousmane Faye, has strengthened the care of skin disease in the country and also provided valuable research into the methods of training used, based on an algorithmic approach to diagnosis and management.

In **Mexico**, under the guidance of Dr Roberto Estrada and colleagues, a similar approach has been developed for the education of primary care teams which is run throughout the state of Guerrero in Southern Mexico, with the support of the regional health department. Again, research carried out by this group has provided a unique insight into the risk and prevalence of skin diseases in poorer countries. No model works in every environment and so these local groups have tried to adapt initiatives to the most practical and effective in each environment. These programmes are based on short periods of training of one or two days. There are other differences. For instance, in Mexico rural health care is often delivered by newly qualified doctors, *pasantes*, and these become the focus for training.

## Meeting Dermatological Need: Other Initiatives

This work is set against national backgrounds of health where the AIDS pandemic, a rising tide of chronic disease such as diabetes, as well as poverty, dominate all health care programmes. In these same areas, skin disease is very common, being among the top three most frequent reasons for an individual to seek medical help. Endemic diseases such as onchocerciasis and lymphatic filariasis are also common and may present with signs and symptoms in the



## The IFD and Community Dermatology

skin. So from its outset, the Foundation was faced with a challenge to develop new approaches to reach the maximum number of patients, utilising clinical or nursing help appropriate to the local conditions and health services.

Together with a German dermatologist, Christoph Bendick, who has spent the past 20 years in Cambodia and who has developed a diploma course in dermatology for local general medical officers, we are currently investigating the possibility of helping another programme in **Cambodia**. Christoph is currently in the process of developing a new training scheme for specialists, together with the national university in Phnom Penh.

The IFD's work includes support of other initiatives, such as training in community dermatology (**Patagonia**) and needs assessment for skin care (**North India**). None of these schemes would have been possible without the work and dedication of a large number of individuals, who often work voluntarily. The Foundation's role has been to initiate, where appropriate, support, advise and help in ways that suit each programme.

While these training initiatives have provided a bedrock for the work of the IFD, other lines have been developed to strengthen the overall goal of improving the care of patients with skin disease. Particularly, links with other organisations with an interest in health work in poor regions have been developed.

One such project is a link with **Médecins sans Frontières** where volunteers in remote areas can seek advice and support for the care of patients with skin problems, using a system established through the University of Zurich. Likewise, in partnership with the **American Academy of Dermatology**, we are addressing the

needs of simple education by provision of treatment and diagnostic guides for the commonest of conditions, which can be used by front line health workers. The challenge has been to provide simple teaching aids that can be adapted to different regions and languages. A further programme is a new collaboration with **WHO** and **Merck** to investigate the potential for control of scabies in areas where it is endemic and very common. Scabies in such areas is associated with severe complications, due to secondary bacterial infection, including nephritis and rheumatic fever, as well as infant septicaemia. At present, the partnership is investigating the potential for effective interventions.

There is a great deal to do and, therefore, raising funds has become a major focus of work. Most of our current funding comes from Dermatology Societies, together with invaluable contributions from industry and individual donors. The IFD has designed and printed its own fund raising materials which are being used to generate the support for the work described here, and to widen the programmes. However, we are delighted that the work of the Foundation was recognised recently, as the IFD was awarded the Astellas Changing Tomorrow Award for 2009. This has enabled us to take on other programmes of work.

Combining forces with the *Community Dermatology* Journal, initiated in 2009, provides a key step in helping to promote continuous education for all involved in the care of patients with skin problems, and as a forum for discussion of dermatological issues relevant to the care of patients in low income countries. The first Issue, as a joint venture, was published in 2009. With the help of colleagues around the world, it is planned to expand the circulation of the Journal, as well as recruiting more authors for future Issues.



## JOURNAL EXTRACTS

Neil H Cox BSc (Hons) FRCP

### Skin Bleaching

**The concept of skin bleaching in Africa and its devastating health implications**

De Souza M M

*Clin Dermatol* 2008; **26**(1): 27-29

It is a strange fact that people with pale skin often want to have a darker colour, whilst those with dark skin often wish to be paler. It is a sad fact that, in either case, some individuals will take advantage of this and use it as a way to make large amounts of money. This paper describes aspects of skin bleaching in Africa, where a white skin is idolized as a sign of wealth and beauty. The author describes use of counterfeit products, altered brand-name products and various unknown mixtures, typically using chemicals such as herbal mixtures, mercury, hydrogen peroxide, steroids, solvents, phenols, hydroquinone and others. Some of these are useless, whilst others are toxic, irritant, contact sensitizers or cause thinning of the skin. The sad thing is that some of these agents are supplied by international syndicates, making large amounts of money. More positively, some African countries are now banning the sale of such products.

### Siddha Treatment in Dermatology

**Siddha medicine – background and principles and the application for skin diseases**

Thas J J

*Clin Dermatol* 2008; **26**(1): 62-78

Chinese medicines and herbal medicines have attracted attention in Western countries but other traditional medical methods have been less widely investigated. This article is a nice overview of Siddha medicine, an ancient medical approach used mainly in Tamil populations in India, and specifically explains its use in dermatology. Diagnosis is made by assessments of pulse, palpation, colour, speech and features of the tongue, eyes, stool and urine. Skin conditions fall into five main groups but do not equate to terms used in English or other languages; some are specific sensations (such as 'burning') rather than conventional diseases. The treatments are herbal or herbal and mineral. The one that stands out is a treatment for tinea, using *Cassia* seed soaked in expressed juice of *Euphorbia* and made into a paste by grinding with cow's urine.



## TRIBUTE : NEIL H COX

### Neil H Cox

We were saddened to hear of Neil Cox's sudden and untimely death. Neil has been a major figure in British Dermatology, a past editor of the *British Journal of Dermatology* and a co-editor of the 'Rook' Textbook of Dermatology.

He unstintingly made his considerable expertise and wide knowledge available to the *Community Dermatology Journal* both as a contributor and member of the Editorial Board.

He regularly and unfailingly provided journal abstracts and contributed review articles, even from his hospital bed. His enthusiastic energy and commitment are all the more remarkable considering his chronic ill-health in recent years. All those who have known Neil will mourn a greatly respected and liked dermatologist.

Dr Paul Buxton  
Dr Christopher Lovell

## HAZARDS OF USING SKIN BLEACHING AGENTS

Mahreen Ameen MPH MD MRCP DTM&H

*Locum Consultant Dermatologist*

*Royal Free Hospital*

*London NW3 2QG*

*United Kingdom*

Email: mahreenameen@hotmail.com

Beatrice Etemesi MBChB MMed

*Consultant Dermatologist*

*Nakuru Provincial General Hospital*

*PO Box 71, Nakuru*

*Kenya*

### Introduction

The use of skin lightening products is common practice in Africa, the Middle East, Asia, the Caribbean and Latin America. Its use is particularly common in sub-Saharan Africa with reported prevalence rates of use between 26-67%.<sup>1,3</sup> Depigmenting agents are mainly used to lighten the skin cosmetically, as in some cultures lighter skin colour is perceived to be associated with social privileges, such as improved job or marriage prospects. They are also used to treat hyperpigmentary problems that can occur after skin diseases, such as acne and eczema have resolved, and some women use them in an attempt to make skin appear more radiant and smoother as 'teint clair' or clear skin is often the standard of beauty promoted in West African magazines. Skin lightening is practiced predominantly by women, but studies report that men use them regularly as well. All socio-professional groups are involved in this practice. Women admit to increasing their cosmetic use of skin lightening products before important events such as weddings and baptisms. Of particular concern are reports of the continued use of these products by pregnant women, and even an increase in use by some pregnant and breast feeding women in preparation for the baptism of their child.<sup>4</sup> Social pressures of maintaining a lighter skin colour, together with a lack of understanding of the constituents of these products, has resulted in a 'high incidence of side effects associated with their use'.

### Constituents of Skin Lightening Agents

Skin lightening formulations contain a diverse range of agents (Table 1). Those that commonly cause complications, potentially serious, include potent corticosteroids (often clobetasol propionate), high-dose hydroquinone (greater than the recommended

5% maximum concentration) and mercurial derivatives. They are present at various concentrations and the product information is often misleading. A study conducted in Paris, France, which reported that skin lightening is widely practised amongst ethnic communities originating from Africa, measured three samples of creams bought from markets and found hydroquinone concentrations of 4.5%, 9% and 16.7%. The packaging of two of the products did not mention the presence of hydroquinone and the third listed only a 2% concentration of hydroquinone.<sup>5</sup> Samples analysed in Senegal found hydroquinone concentrations of 4%-8.7%.<sup>1</sup> In addition to the product package information sometimes being incorrect, the advertising of skin creams is often deceptive with images suggesting that the creams contain natural products only (Figure 1). Even if the contents are correctly labelled, not all patients may be familiar with the names of steroid creams and their potencies. Similarly, even if patients recognise hydroquinone, they may not know what is considered to be a safe concentration to use.

Several studies have reported that the majority of products contain hydroquinone and/or potent topical steroids.<sup>1,3</sup> However, a study from Togo reported that mercury derivatives were a more common agent than either corticosteroids or hydroquinone, and were present in 31% of skin lightening agents. Approximately 25% of products used in Senegal and Togo were of unknown composition.

Studies have demonstrated that those who practice skin lightening often use them at least on a daily basis. In some countries they are commonly used on the body as well as the face; a study in Senegal reported that 92% of users applied them to the whole body.<sup>1</sup> Long term use can cause both cutaneous and systemic side effects, and approximately 70% of users develop complications. Risk factors for developing complications include the type and concentration of lightening agent used, the use of several products at the same time, the length of time that they are used, application all over the body, and sun exposure.

### Cutaneous Side Effects

There are a wide range of side effects on the skin, in particular severe and widespread cutaneous infections and pigmentary problems (Table 2). Multiple complications are common. Corticosteroid use is associated with dermatophyte infections, scabies, pyoderma, acne and striae. A case-control cross-sectional study in Mali demonstrated that striae had the highest risk of occurrence,

# Hazards of Using Skin Bleaching Agents

being 50 times more common in women who bleached their skin compared to controls. The next most common skin complications were mycosis and pyoderma, which were five times more frequent in cases than controls.<sup>2</sup>

**Table 1: Constituents of Skin Lightening Agents**

<b>Potent corticosteroids</b>
<b>Hydroquinone</b>
<b>Hydroquinone derivatives: hydroquinone monomethylether and hydroquinone monobenzylether</b>
<b>Mercurials: mercuric iodide 1-3% or mercuric chloride 6-8%</b>
<b>Retinoic acid</b>
<b>Alpha hydroxyl acids</b>
<b>Kojic acid</b>
<b>Hydrogen peroxide</b>

Clinical presentations of infections are often atypical, severe, difficult to treat, and recurrent. Tinea affecting the face is usually uncommon, but is commonly associated with the use of skin lightening agents. Tinea corporis can be widespread, inflammatory or pustular. Topical corticosteroids can suppress the inflammation of fungal infections and produce 'tinea incognito', an atypical presentation of tinea which loses much of its erythema and scaling because of the anti-inflammatory properties of corticosteroids. Communities where skin bleaching with potent topical steroids is common practice suffer with high rates of scabies infestation, and scabies often presents with widespread pustular or crusted lesions.<sup>1</sup>

Pigmentary problems can be particularly disfiguring and include hyperpigmentation, exogenous ochronosis, and chemical leukoderma.

Hyperpigmentation is usually post-inflammatory and often occurs because hydroquinone can be highly irritating producing an irritant contact dermatitis, especially in higher concentrations. The concomitant use of a corticosteroid usually reduces this effect. Hydroquinone also has a photo-sensitising effect and sun exposure increases the risk of hyperpigmentation. Unfortunately, the product information usually does not advise the use of a sunscreen to minimise the risk of hyperpigmentation. The hyperpigmentation is usually apparent on the forehead, cheekbones and periocular regions of the face.<sup>1</sup>

Exogenous ochronosis presents with an asymptomatic deep blue/black pigmentation in sun-exposed areas. In the late stages, there are numerous tiny black papules. There may also be pigment deposition in the cartilage of the ear (Figure 2). There are characteristic histological changes, with degeneration of the collagen and elastic fibres and deposition of ochre-coloured fibres in the dermis. Ochronosis is a strong indication of the prolonged use of hydroquinone. It is extremely disfiguring and is almost impossible to treat. The majority of reported cases have been from Africa. However, antimalarials may also produce ochronosis, and, therefore, it is possible that some of the cases may have been due to the intake of antimalarials at the same time.<sup>3</sup>



**Fig. 1:** A cream which suggests that it contains natural aloe vera actually contains clobetasol propionate

Photo: Mahreen Ameen

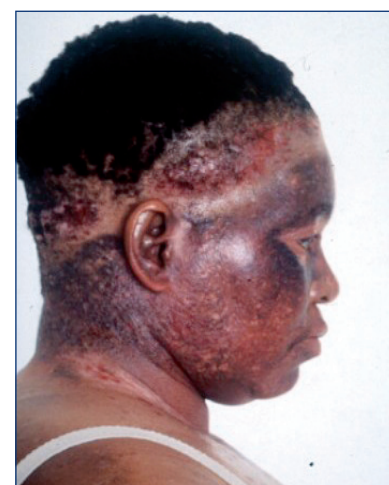Chemical leukoderma has mainly been linked to the use of monobenzylether of hydroquinone [MBEHQ] but can rarely be caused by hydroquinone as well. MBEHQ has, in theory, been withdrawn from cosmetic products, although its adverse effects are still sometimes seen; it can produce confetti-like hypopigmented macules.

## Systemic Adverse Effects

There is a significant risk of percutaneous absorption with regular, long term and all over body application of high concentrations of skin bleaching agents. Adrenal suppression can be induced by a weekly dose of 50g of clobetasol propionate 0.05%.<sup>6</sup> Studies report that the amount of corticosteroids applied to the skin for skin lightening purposes can reach 350g<sup>2</sup> or even 480g<sup>4</sup> per month. Mahé *et al's* study in Senegal reported that the average amount of corticosteroid applied every month was 95g (range 15-350g).<sup>4</sup> Hypertension, diabetes, and low birth-for-weight babies have all been reported in association with potent corticosteroid use.<sup>4,7</sup> In a hospital based study in Dakar, Senegal, patients who had used skin lightening products for more than 10 years had an odds ratio of 1.3 for developing hypertension, and an odds ratio of 3.6 for developing diabetes.<sup>7</sup> There are reports of adrenal insufficiency when skin bleaching is suddenly stopped. The long term application of potent topical steroids to the face can also increase the risks of cataracts, glaucoma and infections.<sup>2</sup>

Animal studies have demonstrated that hydroquinone can cause cancer but there have been no reports linking hydroquinone to cancer in humans.

The renal complications associated with the use of mercurials are well known. In the early 1970s they were the most frequent cause of the nephrotic



**Fig.2:** Severe exogenous ochronosis affecting sun-exposed areas of head and neck. It also affects the cartilage of the ears, and there are striae at the base of the neck

Photo: Mahreen Ameen



# Hazards of Using Skin Bleaching Agents

syndrome in adult women in Kenya. Mercury compounds have also been associated with neurological complications such as insomnia, memory loss and peripheral neuropathy, and there has been a case report of mercury intoxication in a newborn which was attributed to the mother's use of soap containing mercury during pregnancy and lactation.

There has been a reported case of a delay in the diagnosis of leprosy as a result of the application of a skin lightening agent by the patient to treat the hypochromic lesion on her cheek.

## Management

Physicians can detect the use of skin lightening agents in their patients from the characteristic changes to their skin. This can be identified in the early stages when there may be only erythema (as a result of the development of telangiectasia), mild facial hypertrichosis, and hyperpigmentation particularly affecting the cheekbones, forehead and periocular areas. Patients need to be educated on the effects of continued use and that it is extremely difficult to reverse some of the cutaneous complications, particularly the pigmentary problems. Hyperpigmentation should improve with time but patients should be instructed to use a daily high and broad spectrum sun protection factor and practice sun avoidance. However, exogenous ochronosis is permanent.

**Table 2: Skin Diseases Associated with the Use of Skin Bleaching Agents**

<b>Changes to Skin Structure</b>
<b>Skin atrophy</b>
<b>Striae (Figure 2)</b>
<b>Poor wound healing and increased risk of wound dehiscence</b>
<b>Telangiectasia and purpura</b>
<b>Facial hypertrichosis</b>
<b>Disorders of Pigmentation</b>
<b>Hyperpigmentation</b>
<b>Exogenous ochronosis (Figure 2)</b>
<b>Confetti-like hypomelanosis/ leukoderma</b>
<b>Skin Infections and Infestations</b>
<b>Dermatophyte infections</b>
<b>Candidiasis</b>
<b>Pityriasis versicolor (Figure 4)</b>
<b>Intertrigo</b>
<b>Pyoderma</b>
<b>Erysipelas</b>
<b>Scabies</b>
<b>Inflammatory Skin Diseases</b>
<b>Acne vulgaris or rosacea (Figure 5)</b>
<b>Perioral dermatitis</b>
<b>Irritant or allergic contact dermatitis</b>

Abrupt cessation of skin lightening creams that contain potent topical steroids can result in rebound acne vulgaris, which can be very severe. In such cases, patients have developed steroid-induced

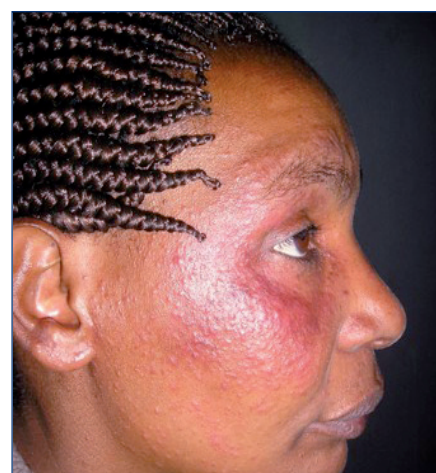acne which has been suppressed with the continued use of corticosteroids. Therefore, long term use of potent topical corticosteroids should not be stopped abruptly. Instead, patients should be gradually weaned off by reducing to weaker concentrations before stopping them altogether. They may also require either topical or systemic treatment as they may develop acne vulgaris. Some dermatologists routinely prescribe a course of systemic antibiotics (e.g., doxycycline 100mg daily or erythromycin 500mg twice daily) to prevent any occurrence of acne, as this will cause further pigmentary problems in this group of patients. Abrupt cessation of long term, all over body use of potent corticosteroids is also associated with the risk of precipitating adrenal insufficiency.

Fungal infections, associated with skin lightening agents, can be so severe and widespread that they may fail to respond to topical antifungal therapy alone and require a short course of oral antifungals.

Pigmentary problems can be particularly disfiguring and include hyperpigmentation, exogenous ochronosis, and chemical leukoderma.

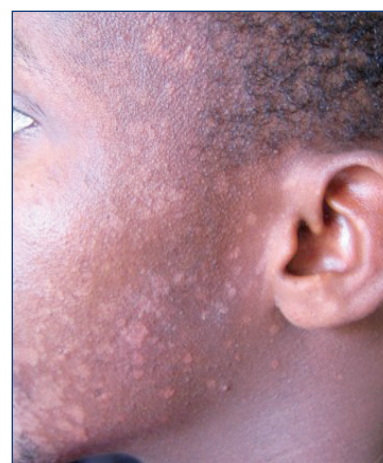## Conclusion

The cosmetic use of skin lightening products can have a huge impact on dermatological services. The proportion of dermatological visits related to complications of the use of bleaching products appears to have significantly increased. In Dakar, Senegal, for example, it comprised only 2% of dermatological consultations in 1976<sup>8</sup> but approximately 25% by 2003.<sup>1</sup> The high incidence of infections associated with their use also has implications for communities, as there is an increased risk of infections to other community members. Potent corticosteroids are associated with the highest incidence of adverse effects. However, high dose or long term use of hydroquinone can produce exogenous ochronosis, which is very disfiguring and for which there is no satisfactory treatment. Being able to clinically identify the inappropriate use of skin lightening agents enables clinicians to



**Fig. 3: Erythema and early hyperpigmentation of the cheeks and a monomorphic acneiform eruption due to topical corticosteroids**

Photo: Mahreen Ameen



**Fig. 4: Pityriasis versicolor of the face and hyperpigmentation of temples**

Photo: Mahreen Ameen

agents enables clinicians to

## Hazards of Using Skin Bleaching Agents

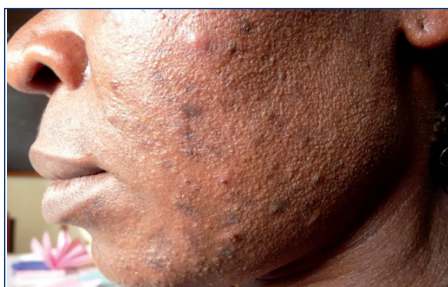

Fig. 5: Acne vulgaris and post-inflammatory hyperpigmentation

Photo: Mahreen Ameen

withdraw them and manage any complications. It is also important to educate patients to seek dermatological care for pigmentary problems rather than to self-medicate.

The distribution of skin lightening products is not regulated, and the majority are found on the informal market. The purchaser or seller may not be aware that these products contain potent corticosteroids or high dose hydroquinone, and that they should be obtained by prescription only. Clinicians need to raise awareness of the public health impact of this dangerous practice and alert government authorities and persuade them to clamp down on the illegal trafficking of bleaching agents.

### References

1. Mahé A., Ly F., Aymard G., Dangou J.M. Skin diseases associated with the cosmetic use of bleaching products in women from Dakar, Senegal. *Br J Dermatol* 2003; **148**: 493–500.
2. Faye O., Keita S., Diakité F.S. *et al.* Side effects of depigmenting products in Bamako, Mali. *Int J Dermatol* 2005; **44**: 35–36.
3. Dadzie O., Petit A. Skin bleaching: highlighting the misuse of cutaneous depigmenting agents. *J Eur Acad Dermatol Venereol* 2009; **23**(7): 741–750.
4. Mahé A., Perret J.L., Ly F. *et al.* The cosmetic use of skin-lightening products during pregnancy in Dakar, Senegal: a common and potentially hazardous practice. *Trans R Soc Trop Med Hyg* 2007; **101**: 183–187.
5. Petit A., Cohen-Ludmann C., Clevenbergh P. *et al.* Skin lightening and its complications among African people living in Paris. *J Am Acad Dermatol* 2006; **55**(5): 873–878.
6. Carruthers J.A., August P.J., Staughton R.C. Observations on the systemic effect of topical clobetasol propionate (Dermovate). *BMJ* 1975; **4**: 203–204.
7. Raynaud E., Cellier C., Perret J.L. Dépigmentation cutanée à visée cosmétique. Enquête de prévalence et effets indésirables dans une population féminine Sénégalaise. *Ann Dermatol Venereol* 2001; **128**: 720–724 (French).
8. Marchand J.P., N'Diaye B., Arnold J., Sarrat H. Les accidents des pratiques depigmentation cutanée cosmétique chez la femme africaine. *Bull Soc Med Afr Noire Lang Fr* 1976; **21**: 190–199 (French).



## HUMAN DERMAL MYIASIS

Christopher R Lovell MD FRCP  
Consultant Dermatologist  
Royal United Hospital NHS Trust  
Bath, BA1 3NG  
United Kingdom

### Introduction

Myiasis is defined as infestation by larvae of diptera flies. Many flies, such as houseflies, which lay their eggs in decaying matter, can also colonise cavities, such as the ear, nasopharynx or urogenital tract, or wounds, such as leg ulcers and ulcerated malignancies (**facultative myiasis**). Some species colonise the conjunctivae, and may even penetrate the anterior or posterior chambers of the eye, causing visual impairment. Ingestion of eggs or larvae, leading to intestinal colonisation, is an example of **accidental myiasis**. Larvae of a few fly species can only develop in mammalian tissue; this is termed **obligate myiasis**. These species are a major cause of morbidity in livestock and are the most important in medical practice.

Facultative myiasis can occur in neglected ulcers and wounds, particularly in the tropics. Maggots can effectively reduce wound slough and 'larval therapy' has proved an effective form of ulcer debridement. Cutaneous myiasis is usually caused by obligatory parasites. The commonest form is **furunculoid** (boil-like) **myiasis**. Usually, larvae develop in the area of skin where they penetrate, although genera such as *Hypoderma* may migrate to the skin from the gastro-intestinal tract. Sometimes *Hypoderma* larvae move slowly through sub-cutaneous tissue, inducing a florid urticarial response, sometimes with eosinophilia; this is distinct from 'creeping erup-

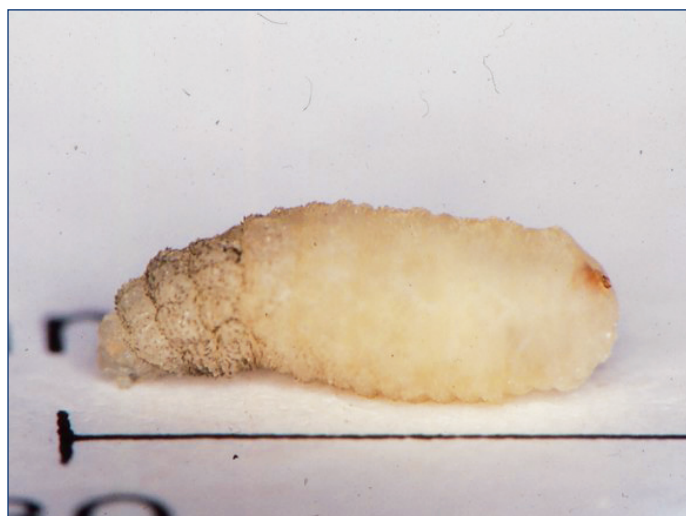

Fig. 1: Larva of *Cordylobia anthropophaga*, extracted from a European businessman who was working in the Congo

Photo: Chris Lovell

tion' or larva migrans, which is caused by nematode larvae. This brief review concentrates on furunculoid myiasis.

### Geographical Distribution

Myiasis occurs worldwide, but it is most commonly encountered in the tropics. The commonest species of human importance are the tumbu fly (*Cordylobia anthropophaga*), found in sub-Saharan Africa (although a case has been reported recently from Portugal) and human botfly (*Dermatobia hominis*) in central and southern America. Old-world screw worms (*Chrysomya bezziana*) are the major cause of myiasis in India, also occurring elsewhere in tropical Asia and Africa. The female fly lays her eggs in open wounds, and the larvae burrow into surrounding tissues. New-world screw



# Human Dermal Myiasis

worms (*Cochliomyia* spp.) occur in the American tropics; *C. hominivorax* (*americana*) can produce furunculoid lesions. Congo floor maggots (*Auchmeromyia luteola*), native to sub-Saharan Africa, lay their eggs on soil or sand floors in huts; the blood-sucking larvae attack those who sleep on the floor. This can be prevented by raising the bed even a few centimetres. Warble flies (*Hypoderma* spp.) occur in Europe and Asia. They are important to cattle farmers as they can reduce milk production and damage hides. Flesh flies (*Wohlfahrtia* spp.) occur chiefly in the Mediterranean basin and Middle East; they can cause furunculoid myiasis in children.

Apart from causing discomfort, lesions of myiasis can become secondarily infected; multiple lesions can induce a febrile illness, especially in children.

**Tumbu fly** (*Cordylobia anthropophaga*), or mango fly, is dull yellow with brown markings on the abdomen. It lays its eggs on soil (particularly if contaminated by urine or faeces) or on washing hung out to dry. The larvae penetrate intact skin using hooks on their mouthparts. The trunk, buttocks and proximal thighs are predominantly affected, often by multiple lesions. After 2-3 days a small papule develops, which then becomes painful and boil-like; one or more cylindrical larvae (Figure 1) can be seen beneath the punctum of each lesion. The larvae fall out of the boil in 7-10 days and pupate on the ground, hatching after a few days. Tumbu fly larvae affect people who sit or lie on contaminated ground, but eggs can hatch on those who wear contaminated clothes (warm ironing is recommended!). *Cordylobia rodhainii* (Lund's fly) causes similar, but more painful lesions because of its spiny larvae. It is endemic to African rain forest regions.

It is usually possible to extract *Cordylobia* larvae by applying gentle pressure around the margins of the lesion. Improved hygiene and sanitation can reduce the incidence of infestation. It is worth considering oral ivermectin in a patient with multiple lesions.

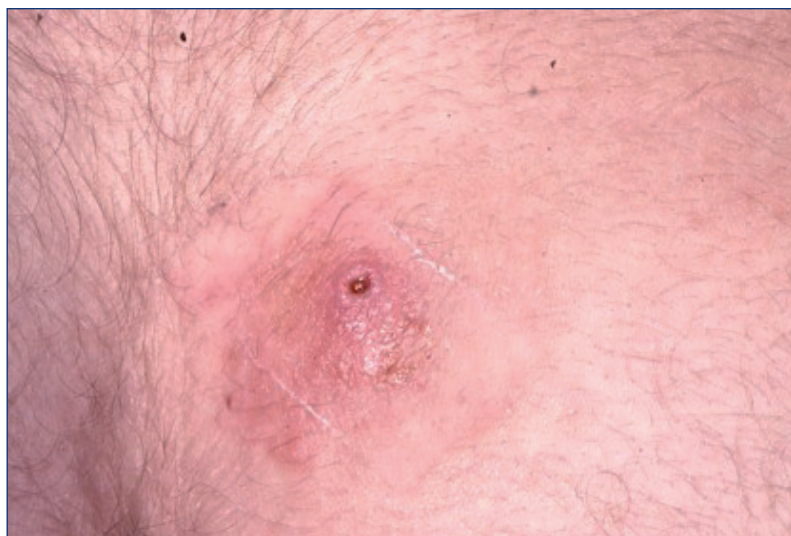

Fig. 2: Truncal furunculoid lesion due to *Dermatobia hominis*

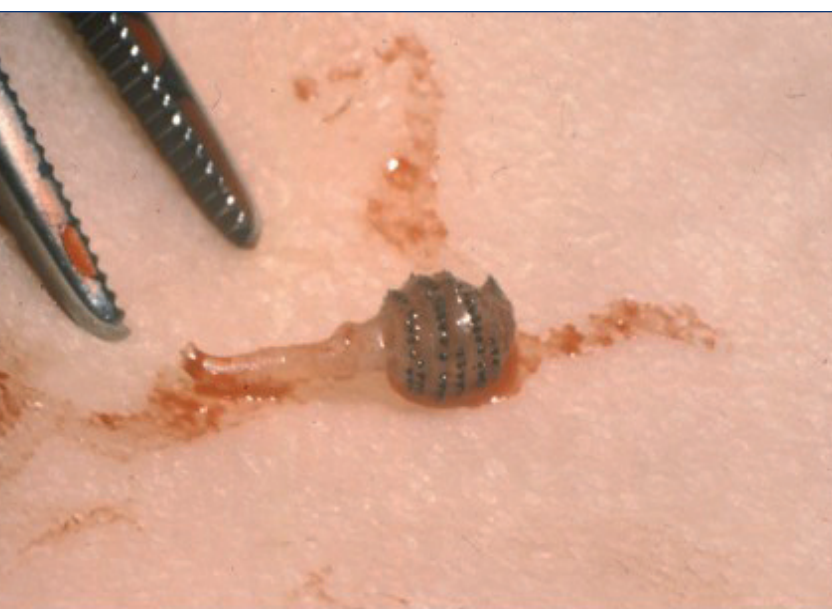

Fig. 3: Larva of *Dermatobia hominis*, extracted surgically from the lesion in Fig. 2. Note the multiple spines

Photo: Chris Lovell

**Human botfly** (*Dermatobia hominis*)<sup>1</sup> is a large bluebottle-like fly, favouring warm humid areas throughout central and southern America. It is a major parasite of cattle. The female fly captures a mosquito or other blood-sucking insect in mid air and glues her eggs on its abdomen. When the vector settles on a warm-blooded host, the eggs hatch rapidly and the larvae enter the skin either via the puncture wound or through intact skin (Figure 2). Exposed sites are favoured, such as the head and neck, forearms and legs. After developing for between 7-10 weeks, the larvae fall out of the skin, pupate and hatch after another 2-3 weeks. The mature larvae (Figure 3) are pear-shaped, with rows of backward-pointing spines. Rotation of the larva causes attacks of severe pain, often in the morning and evening; the lesion often becomes secondarily infected, producing a foul-smelling bubbling exudate.

*Dermatobia* larvae are difficult to express, because of their shape and spiny surface. Sometimes it is possible to suffocate the larva with animal fat or mineral oil. Where possible it is best to enlarge the punctum with a cruciate incision and carefully remove the intact larva. Topical antiseptics and irrigation of the wound is desirable. Sometimes the larva can be removed after injecting the base of the wound with local anaesthetic. In a recent case report,<sup>2</sup> topical ivermectin killed multiple *Dermatobia* larvae and aided extraction in an HIV-infected patient.

## References

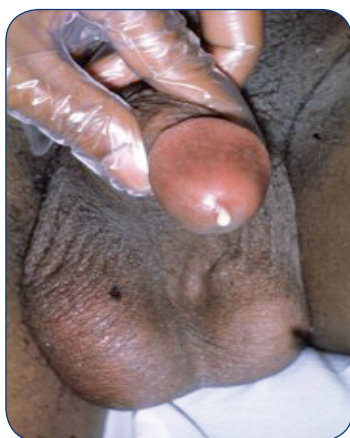1. Lane, R.P., Lovell C.R., Griffiths W.A.D. *et al.* Human cutaneous myiasis: a review and report of three cases due to *Dermatobia hominis*. *Clin Exp Dermatol* 1987;**12**: 40-45.
2. Clyti E., Nacher M., Merrien L. *et al.* Myiasis owing to *Dermatobia hominis* in an HIV-infected subject. Treatment by topical ivermectin. *Int J Dermatol* 2007; **46**: 52-54.

Photo: Chris Lovell

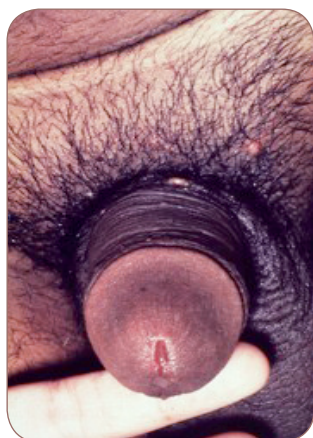

## QUIZ: GENITAL LESIONS

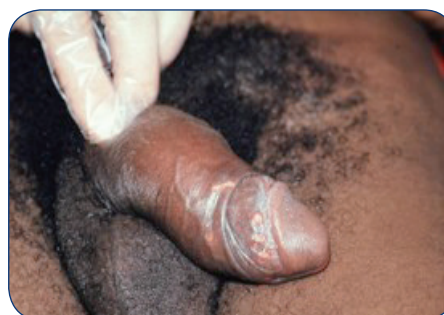## Questions



1



2



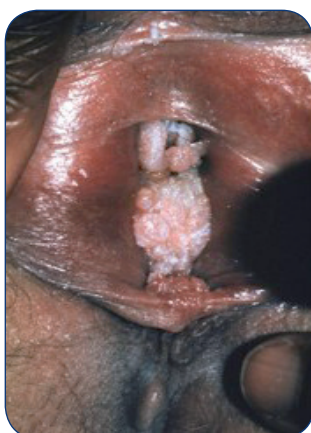3

**Dr Kassahun Desalegn Bilcha**  
Consultant Dermatologist  
University of Gondar  
Gondar, Ethiopia

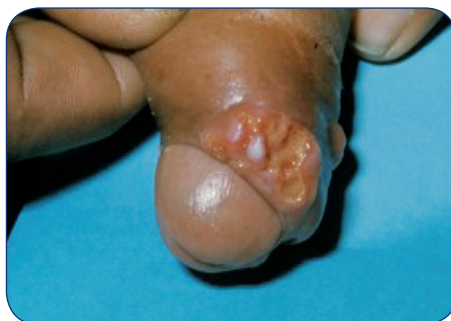### QUESTIONS:

1. Persistent urethral discharge. Tender enlargement of the right testicle.
2. Urethritis – non symptomatic.  
Lesions on the pubic area.
3. Persistent, painful vesicles and erosions.
4. Vulval and vaginal lesions in a pregnant woman.  
What test should be done?
5. Enlarging, irregular, painful ulcer.  
What is the differential diagnosis?

ANSWERS on Page 23



4



5

*anthropophaga*

## SCABIES AND MYIASIS AMONG RURAL COMMUNITIES OF DELTA STATE IN NIGERIA

**Lucy Airauhi PhD**  
Senior Lecturer  
School of Medicine, University of Benin  
Nigeria

Email: yununica@yahoo.com

**A O Airauhi MBBS**  
Department of Medical Microbiology and Parasitology  
School of Medicine, University of Benin  
Nigeria

### Introduction

Parasites that infest the human skin are collectively called ectoparasites which belong to the phylum - *Arthropoda*. Infestations are common in developing countries because prevailing climatic and socio-economic factors favour transmission all year round. Ectoparasites are of considerable public health importance in Nigeria. In Zaria, northern Nigeria, Audu *et al*<sup>1</sup> documented scabies among school children, while Airauhi *et al*<sup>2</sup> in Benin City, Southern Nigeria, reported scabetic infestations among patients seen in hospital out-patient clinics.

Complications of ectoparasitoses predispose sufferers to life threatening illnesses when there is bacterial co-infection. The aetiology of scabies involves a wingless mite, *Sarcoptes scabiei*. The adult, fer-

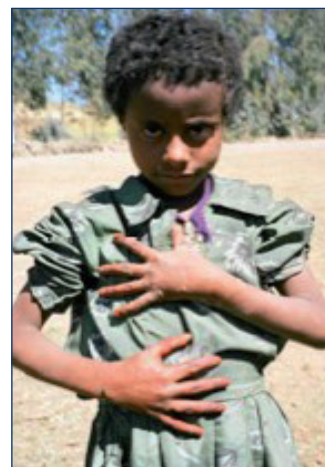tilised females burrow into the skin laying eggs - with associated blisters and symptoms of intense itching. Scabies often spreads by close contact with infected articles or persons.

Furuncular myiasis of the breast due to infestation by the larva of *Cordylobia anthropophaga*, mimicking breast cancer was reported in Jos, Northern Nigeria.<sup>3</sup> In Gambia, bacterial co-infected complicated scabies was associated with immune responses that predisposed children to post-infective nephropathy (PIN).<sup>4</sup>

This paper documents scabetic and myiasis infestations in rural Nigerian communities and emphasises the need for healthy skin through good personal and general hygiene, as well as appropriate treatment practices.

### Materials and Methods

The study was conducted over a 2-year period, between March 2005 and February 2007, in



Scabies

Photo: Tropical Health and Education Trust

# Scabies and Myiasis in Nigeria

Southern Nigeria. There were 1035 participants, aged 61 years and below residing in a previously described focus endemic for sleeping sickness.<sup>5</sup> Survey questionnaires were documented for each study participant. The study required home visits which allowed for the assessment of living conditions, source of water supply, personal and general hygiene. Adult respondents were engaged in non-elite occupations - drivers, fishermen/women, market women, traders, etc. The majority had no formal education. Others attended primary and junior secondary education. Other information recorded were age, sex, village community, symptoms, complaints, infestation site, duration of infestation and treatment practices.

## Specimen Collection and Identification

Scabies mites and myiasis larvae were collected into labelled bottles, preserved with alcohol and then examined microscopically after cleaning and mounting on microscope slides. Species of adult *Sarcoptes scabiei* mites and posterior spiracles of *Cordylobia anthropophaga* larva were identified, based on characteristic morphological features consistent with the species as previously described.<sup>6</sup> Data were analysed by parametric tests (students t-test). The level of significance was  $p < 0.05$ .

## Ethical Clearance

Our study protocol was approved by the Review Board of the Ethical Committee of the University of Benin Teaching Hospital, Benin City.

## Results

The total number of cases of scabies was 218 (87.5%). Myiasis accounted for 31 (12.5%) cases. Thus, 249 of 1035 volunteers enrolled for the study were infested.

The demographic profile for the study and infested populations revealed that there were more males than females but with no significant sex predisposition in either case ( $p > 0.05$ ). The ages of the participants ranged between 0-61 years. Proportionately more subjects were aged between 0-20 years, therefore, most parasitic skin infestations occurred within this age group. Scabies was most prevalent among those within the first two decades of life, whereas myiasis occurred more frequently among children aged less than 10 years (Table 1).

**Table 1: Demographic Characteristics of those with Scabies (n=217) and Myiasis (n=31)**

Age group (yrs)	Scabies M%	Scabies F%	Myiasis M%	Myiasis F%	Total M%	Total F%
0-10	6(82.1)	44(84.6)	10(17.8)	8(15.4)	56	52
11-20	38 (97.4)	33(86.8)	1(2.6)	5(13.2)	39	38
21-30	16(88.8)	20(100.0)	2(11.1)	0(0.0)	18	20
31-40	4(80.0)	8(88.8)	1(20.0)	1(11.1)	5	9
41-50	5(71.4)	3(100.0)	2(28.6)	0(0.0)	7	3
51-60	0(0.0)	0(0.0)	1(100)	0(0.0)	1	0
>60	0(0.0)	0(0.0)	0(0.0)	0(0.0)	0	0

**Table 2: Ectoparasites and Associated Risk Factors for Infestations**

	No. of Subjects	PPH (%)	PGH (%)
Scabies	218	130 (52.2)	88 (35.3)
Myiasis	31	14 (5.6)	17 (68)
Total	249	144	105

## Predispositions to Infestation

Most of the scabetic infestations were associated with subjects with poor personal hygiene (PPH), as seen in 130 (52.2%) cases and poor general hygiene (PGH) in 88 (35.5%) cases, while myiasis was associated with poor personal hygiene among 14 (5.6%) subjects and 17(6.8%) were associated with poor general hygiene.

Lack of good personal and general hygiene, are the major factors which put people at risk of infestations with the *Sarcoptes* and *Cordylobia*. Most of the houses were poorly constructed and children slept in overcrowded rooms. The level of hygiene was poor, clothes were spread on the grass to dry and worn without ironing (Table 2).

## Treatment Practices

The majority (64.2%) of scabetic infestations were inappropriately treated with non-effective balms and lotions, while 25.2% were not treated at all because lesions were expected to clear spontaneously, even when they complained of severe itching. Only 10.6% of the cases were treated appropriately. In all of the cases of myiasis infestation, larvae were extracted from infested sites but associated wounds were often left to heal unhygienically (Table 3).

## Discussion

Among these rural dwellers who were of low socio-economic status, the reasons for unsatisfactory treatment practices ranged from extreme poverty to lack of interest, since most of the respondents did not see why they should worry about a disease that is not life threatening. Most of the respondents complained of lack of financial resources to seek proper health care needs.

Ectoparasitosis is not considered significant and so people often did very little or nothing to treat scabies and myiasis. This is evidenced by the practices recorded in this study, with only 10.6% of cases of scabies treated appropriately.

It is likely that most scabetic lesions in our study area became complicated by bacterial co-infections. Further dermatological studies are necessary to prevent complications in these communities. Our report of scabies among those aged 20 years and below supports earlier findings.<sup>1</sup> High rates of scabetic infestations in our study area are most likely due to inappropriate treatment practices and neglect, based on the assumption that infestations could clear spontaneously. There is an urgent need to enlighten these



# Scabies and Myiasis in Nigeria

respondents that scabies is not curable without prescription medication.

Scabies does become secondarily infected with bacteria, often as a result of an obvious lack of hygiene, itchiness and scratching, which often lead to initiation of immunological mechanisms that can subsequently affect the kidneys.<sup>4</sup>

In considering the significance of this study, several vital limitations must be considered and addressed:

- While our population based study documents scabies and myiasis, it is likely to be an underestimate of the actual prevalence.
- It documents the importance of skin disease among rural dwellers who assume, however, that these infestations are not a cause for worry.
- Yet another important limitation is the general attitude of the population towards research, as they believe that volunteering to be included in the study could reveal various diseases that could lead to ostracisation (shunning; keeping out or away from) of sufferers. Consequently, only small sizes of populations consent to taking part in surveys in this area.
- This study did not investigate the pattern of concomitant infections because it was outside the scope of the study. Our study demonstrates an obvious need for more dermatological studies at community levels which should focus on adequate management for dermatological manifestations of various diseases.

## Acknowledgements

The authors acknowledge the support and co-operation of the study participants and the contributions of field staff.

**Table 3: Treatment Practices for Scabies and Myiasis\* among Rural Communities in Nigeria**

	<b>Scabies (n = 218)</b>	<b>*Myiasis (n= 31)</b>
<b>Appropriate treatment</b>	<b>23 (10.6)</b>	<b>0 (0.0)</b>
<b>Inappropriate treatment</b>	<b>140 (64.2)</b>	<b>31 (100.0)</b>
<b>No treatment</b>	<b>55 (25.2)</b>	<b>0 (0.0)</b>

\*Myiasis larvae were manually extracted unhygienically

## References

- Audu L.I., Ogala W.N., Yakubu A.M., Risk factors in the transmission of scabies among school children in Zaria, Nigeria. *J Paediatrics* 1997; **92**: 35-39.
- Airauhi L.U., Onunu A., Otabor C. Parasitic Dermatoses as seen at the University of Benin Teaching Hospital(UBTH), Benin City, Nigeria. *Afr J Clin Exp Microbiol* 2003; **4**(1): 24-29.
- Ugwu B.T., Nwandiari P.O. *Cordylobia anthropophaga* mastitis of the breast mimicking breast cancer: case report *East Afr Med J* 1999; **76**(2): 115-116.
- Ameyaw S.K. Childhood skin infections and post infective nephropathy. *Trop Doct* 2005; **35**(2): 126.
- Airauhi L.U., Akhigbe K.A., Ofili A.N., Airauhi O.D., Sleeping sickness in the Abraka Belt, Delta State, Nigeria. A preliminary geographical description of the disease focus. *Ann Biomedical Sci* 2002; **1**(2): 111-117.
- Service M.W. A Guide to Medical Entomology, 1979. Second Edition. Macmillan, London.

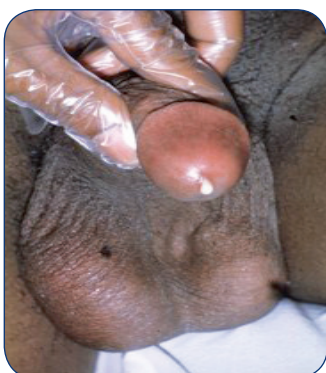□

## QUIZ: GENITAL LESIONS

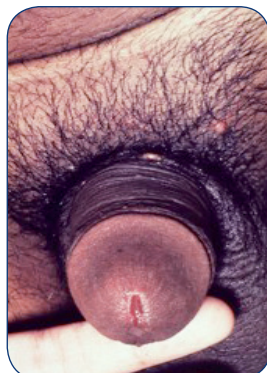
## Answers

### ANSWERS:

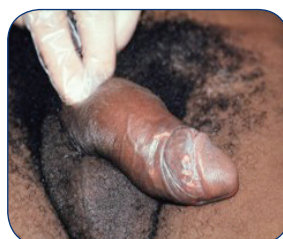- Gonorrhoea – right epididymo-orchitis*
- Chlamydia urethritis. Molluscum contagiosum, pubic area.*
- Herpes genitalis ulcers.*
- Genital warts in pregnancy. Test for HPV (human papilloma virus).*
- Chancroid in a young Indian male. Differential diagnosis: syphilitic chancre (not painful).*



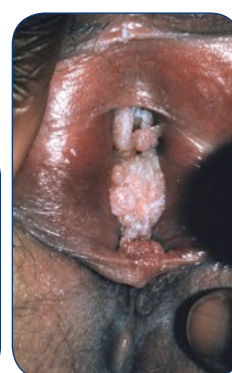
1



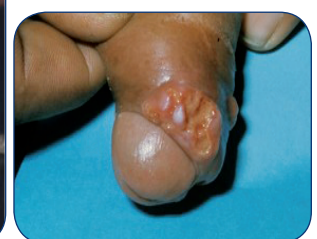2



3



4



5

International Foundation  
for Dermatology  
www.ifd.org



Willan House, 4 Fitzroy Square, London W1T 5HQ, UK

## Editor

Dr Paul Buxton

## Editorial Board

Professor Steven Ersser

Dr Claire Fuller

Dr Sam Gibbs

Dr Richard Goodwin

Professor Rod Hay

Dr Barbara Leppard

Dr Chris Lovell

Dr Murray McGavin

Dr Rachael Morris-Jones

Dr Michele Murdoch

Ms Rebecca Penzer

Professor Terence Ryan

Dr Michael Waugh

## International Advisory Board

Dr Kassahun Desalegn Bilcha  
(Ethiopia)

Professor Donald Lookingbill (USA)

Professor Aldo Morrone (Italy)

Professor Ben Naafs  
(The Netherlands)

Professor Gail Todd (South Africa)

Dr Shyam Verma (India)

## Editorial Secretary

Mr John Caulfield

## Production by World Care Consultancies

Editorial Consultant

Dr Murray McGavin

Associate Consultants

Mrs Carrie McGavin Stow

Mrs Ruth McGavin

Mr Jeff McNeil Stow

## Design / DTP / Printing

Square Dot CTP Services Ltd

Nicosia, Cyprus

fastplate@cytanet.com.cy

ISSN 1743 - 9906

An International Journal for Community Skin Health

# Community Dermatology



*J Comm Dermatol* 2009; 6: 13-24 Issue No. 10

## Guidelines for Authors

The **Editorial Board** welcomes original **articles, reports and letters**. All contributions are reviewed before publication. Original articles should not exceed 1,200 words; short reports/letters should not exceed 500 words.

## Contributions

Contributions should be sent to **Mrs Eve Arnold**, from whom detailed Guidelines for Authors can be obtained.

**Community Dermatology**  
International Foundation for  
Dermatology  
4 Fitzroy Square  
London W1T 5HQ  
United Kingdom

Tel.: +44 (0) 207 7388 6515  
Fax: +44 (0) 207 7388 3213

Or by Email to:  
editor.commderm@ifd.org

*We look forward to  
receiving your articles,  
reports and letters!*



## Distribution

### Mailing List

The Journal is **distributed free of charge** to health care workers, especially in rural communities, in **developing countries**.

## Funding

### Subscriptions

The Journal is funded entirely by **voluntary donations and sponsorship**. We welcome **individual subscriptions** (minimum £25 per annum) to enable publication and distribution to readers in developing countries. If you pay UK tax we can retrieve **Gift Aid** at no extra cost to you.

To join the **mailing list** or **subscribe** to the journal, please contact:  
**Mrs Eve Arnold** (address above)

## © Community Dermatology

Articles may be photocopied, reproduced or translated provided these are not used for commercial or personal profit. Acknowledgements should be made to the author(s) and to **Community Dermatology**